

Shoulder ultrasonography: A comprehensive review of scanning technique and normal findings

Poster No.: C-1919
Congress: ECR 2017
Type: Educational Exhibit
Authors: P. G. Oliveira, M. Cruz, C. Ferreira, C. Ruivo, F. Caseiro Alves; Coimbra/PT
Keywords: Education and training, Technical aspects, Education, Ultrasound, Musculoskeletal joint, Anatomy
DOI: 10.1594/ecr2017/C-1919

Any information contained in this pdf file is automatically generated from digital material submitted to EPOS by third parties in the form of scientific presentations. References to any names, marks, products, or services of third parties or hypertext links to third-party sites or information are provided solely as a convenience to you and do not in any way constitute or imply ECR's endorsement, sponsorship or recommendation of the third party, information, product or service. ECR is not responsible for the content of these pages and does not make any representations regarding the content or accuracy of material in this file.

As per copyright regulations, any unauthorised use of the material or parts thereof as well as commercial reproduction or multiple distribution by any traditional or electronically based reproduction/publication method is strictly prohibited.

You agree to defend, indemnify, and hold ECR harmless from and against any and all claims, damages, costs, and expenses, including attorneys' fees, arising from or related to your use of these pages.

Please note: Links to movies, ppt slideshows and any other multimedia files are not available in the pdf version of presentations.

www.myESR.org

Learning objectives

To present a description of the ultrasonography technique that can be effective in evaluating the shoulder, illustrated with didactic schemes and illustrations of the correct positioning of the probe.

The normal anatomy of the articular structures of the shoulder will be reviewed and a checklist protocol will be proposed.

Background

The ultrasonography (US) is an important imaging modality to evaluate pathologic conditions of the shoulder, with the advantages of good spatial resolution, clinical correlation and dynamic assessment of disease, especially in the rotator cuff disease. When performed with appropriate equipment by skilled operators, US is widely recognized as a means of accurately assessing rotator cuff disease, with a sensitivity and specificity as high as 90%-95%.

The accuracy is dependent on the technique and the skill and experience of the individual performing the ultrasonography examination that must have a very good knowledge of shoulder anatomy and familiarity with normal imaging findings and imaging pitfalls. To reduce individual accuracy variability, it is usually recommended to follow a scanning protocol that includes a list of main structures.

Findings and procedure details

Dynamic ultrasonography is performed with varying degrees of patient arm rotation and joint stress maneuvers. Patient positioning must be comfortable for both the patient and operator. Most authors prefer to scan facing the front of the patient rather than behind the patient.

Probe frequency selection depends on the patients build, but a multifrequency linear transducer (9-12Mz) is usually appropriate for US shoulder evaluation. Uncommonly a 9-MHz transducer is required for extremely large patients to allow depth penetration (with less resolution).

The basic objectives for each step are to identify the tendon of interest in two planes, eliminate artifact (the most common relates to anisotropy) and diagnose disease. A scanning protocol should include the following checklist of key structures:

- Long head of the biceps tendon
- Subscapularis tendon
- Supraspinatus tendon
- Rotator interval
- Acromioclavicular joint
- Subacromial impingement
- Infraspinatus and teres minor tendons
- Posterior glenohumeral joint recess

1. LONG HEAD OF THE BICEPS TENDON

The long head of the biceps tendon (LHBBT) is usually the first structure to be examined, followed by assessment of the tendons of the four rotator cuff muscles.

ANATOMY

The long head of biceps brachii tendon (LHBBT) arises from the supraglenoid tubercle of the scapula and from the superior glenoid labrum as a long tendon, which runs into the joint cavity of the shoulder, between the humeral head and the joint capsule. Then it passes up along the bicipital groove. The tendon is intra-articular but extrasynovial, with a surrounding synovial-lined sheath that communicates with the glenohumeral joint and extends into the bicipital groove.

TECHNIQUE AND EVALUATION

The US assessment is performed with the arm in neutral position. The patient must place his hand palm up on the lap, with the elbow joint flexed at 90°.

The transducer is placed in the axial plane over the anterior humeral head and starts by searching for the biceps tendon in the groove (localized between small and large tuberosity of the humerus). The long head of the biceps tendon appears as an ovalar hyperechoic structure within the groove and small amounts of fluid can normally be seen surrounding the tendon. The mean value of normal tendon thickness is 4.3 mm, but it may vary. Then, the transducer must be rotated 90° to obtained a longitudinal view - long axis of the LHBBT. Both transverse and longitudinal views should evaluate the vertical part of the LHBBT up to the myotendinous junction.

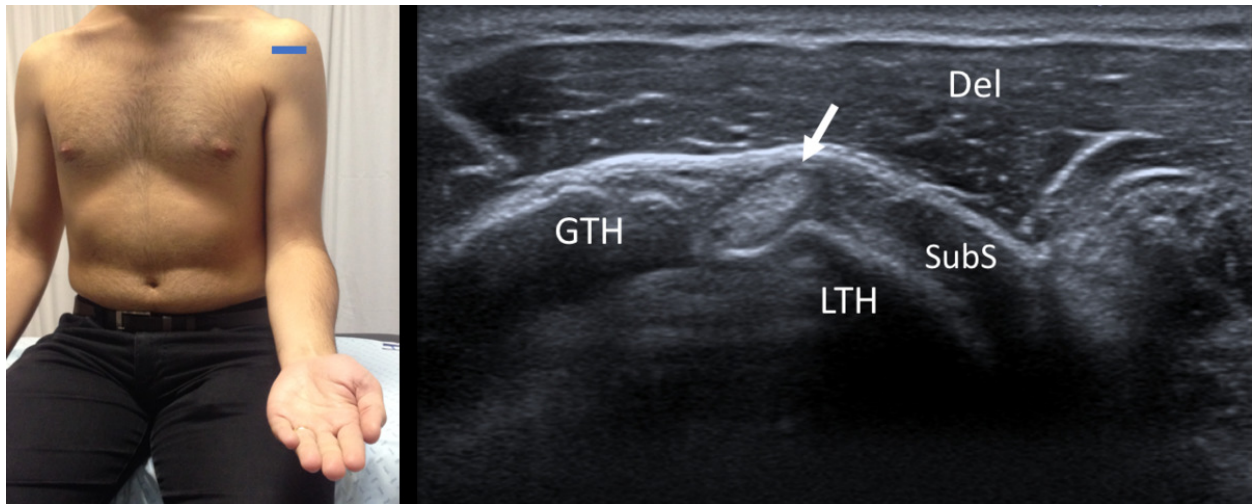


Fig. 1: Short axis of long head of the biceps tendon - Probe placement and US normal imaging findings. LTH, lesser tuberosity of the humerus; GTH, greater tuberosity of the humerus; Del, deltoid muscle; SubS, Subscapularis tendon; Arrow, long head of the biceps tendon

References: Radiology Department, Coimbra University Hospital - Coimbra/PT

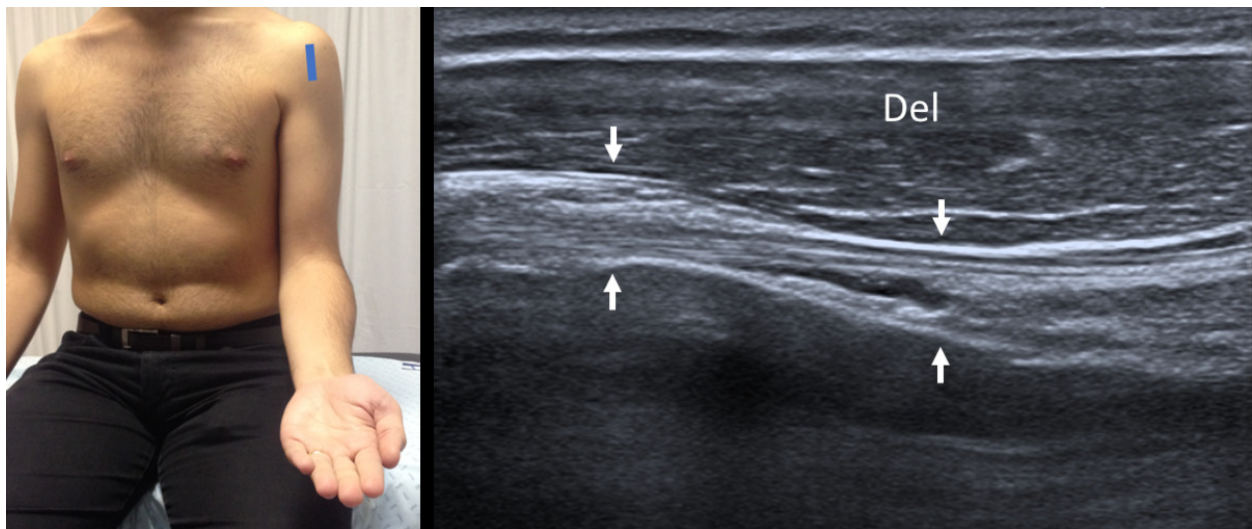


Fig. 2: Long axis of long head of the biceps tendon - Probe placement and US normal imaging findings. Del, deltoid muscle; Arrows, long head of the biceps tendon

References: Radiology Department, Coimbra University Hospital - Coimbra/PT

The fibrillary pattern of the biceps tendon may appear hypoechoic in the longitudinal view due to probe angulation (anisotropy), and usually is needed to pressing on the inferior aspect of the probe to ensure that the ultrasound beam is perpendicular to the biceps tendon. These technical aspects will promote a homogeneous and normal echogenic fibrillar pattern and obtain better evaluation of the tendon.

2. SUBSCAPULARIS TENDON

ANATOMY

The subscapularis muscle arises from the subscapular fossa. The fibers run obliquely and laterally, crossing the front of the glenohumeral joint and forming a tendon which inserts into the lesser tuberosity of the humerus.

TECHNIQUE AND EVALUATION

The patient must rotate the arm externally fixing the elbow on the iliac crest to visualize the subscapularis from its insertion into the lesser tuberosity to the point at which it becomes hidden by coracoid process medially. The transducer is placed on the anterior shoulder, approximately at the level of the coracoid process, in a transverse orientation to scan the long-axis. The transducer is then turned 90° to evaluate its short axis (sagittal plane). The two planes must be evaluated during passive external and internal rotation, with the arm adducted, and the transducer must be moving superior and inferior to ensure a complete evaluation and the tendon integrity. The hypoechoic subscapularis muscle, which interdigitates with its multiple hyperechoic tendons, or tendon anisotropy should not be misinterpreted as disease.

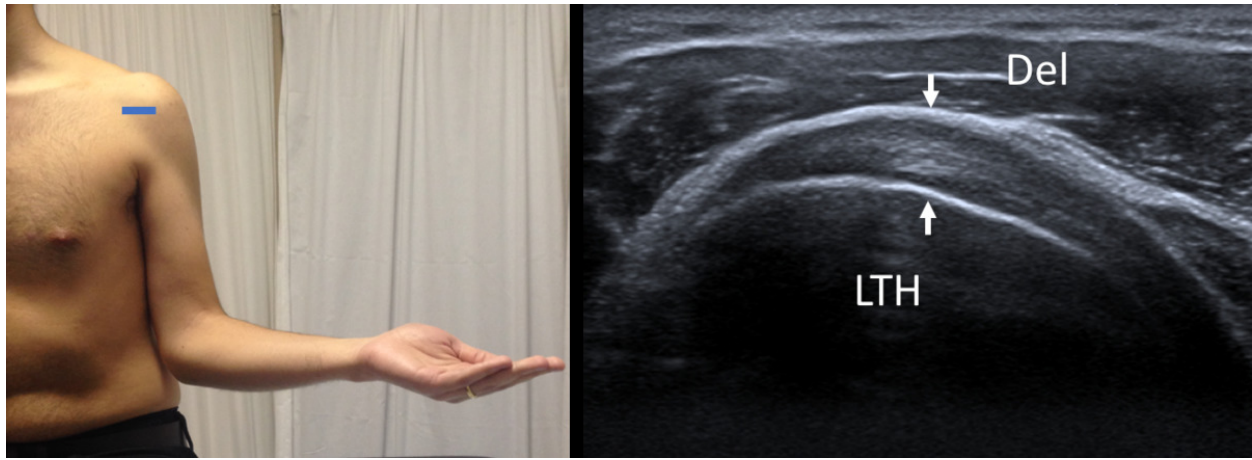


Fig. 3: Long axis of subscapularis tendon - Probe placement and US normal imaging findings. Del, deltoid muscle; LTH, Lesser tuberosity of the humerus; Arrows, subscapularis tendon.

References: Radiology Department, Coimbra University Hospital - Coimbra/PT

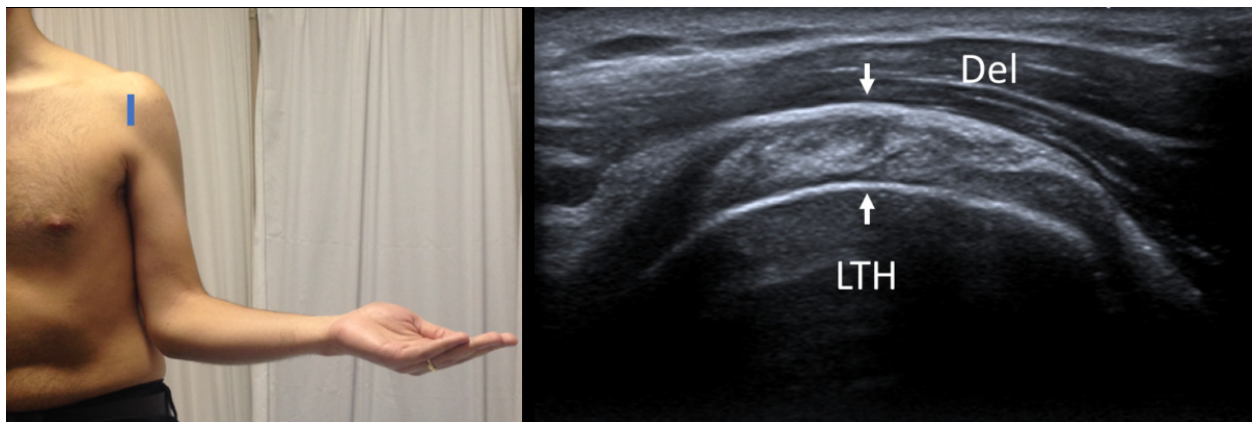


Fig. 4: Short axis of subscapularis tendon - Probe placement and US normal imaging findings. Del, deltoid muscle; LTH, Lesser tuberosity of the humerus; Arrows, subscapularis tendon.

References: Radiology Department, Coimbra University Hospital - Coimbra/PT

3. SUPRASPINATUS TENDON

ANATOMY

The supraspinatus tendon arises from the supraspinatous fossa and runs laterally under the acromial process and behind the clavicle lateral edge, inserting on the most superior facet of the greater tubercle of the humerus.

TECHNIQUE AND EVALUATION

The patient's arm must be posteriorly, with flexed elbow and the palm side of the hand placed on the ipsilateral superior aspect of the iliac wing and directed toward the midline of the back. In this position, the supraspinatus rotates and becomes more anteriorly situated structure, the acromion is moved away from the tendon and is visualized in its full extent.

The evaluation must be performed in two planes, to visualize the tendon in long and short axis. The greater tuberosity and the humeral head are very important bone landmarks during the supraspinatus tendon evaluation. The thickness of the supraspinatus tendon varies from 6-6.5 mm, measured at 2 cm proximally to its insertion on the greater tuberosity. The long-axis view of the supraspinatus allows an accurate characterization of a tear (articular, bursal, intrasubstance, or full-thickness).

The normal supraspinatus should be fibrillary and hyperechoic with a convex superior surface, although some areas may appear hypoechoic due to anisotropy and the probe will need to be angled to avoid this artifact.

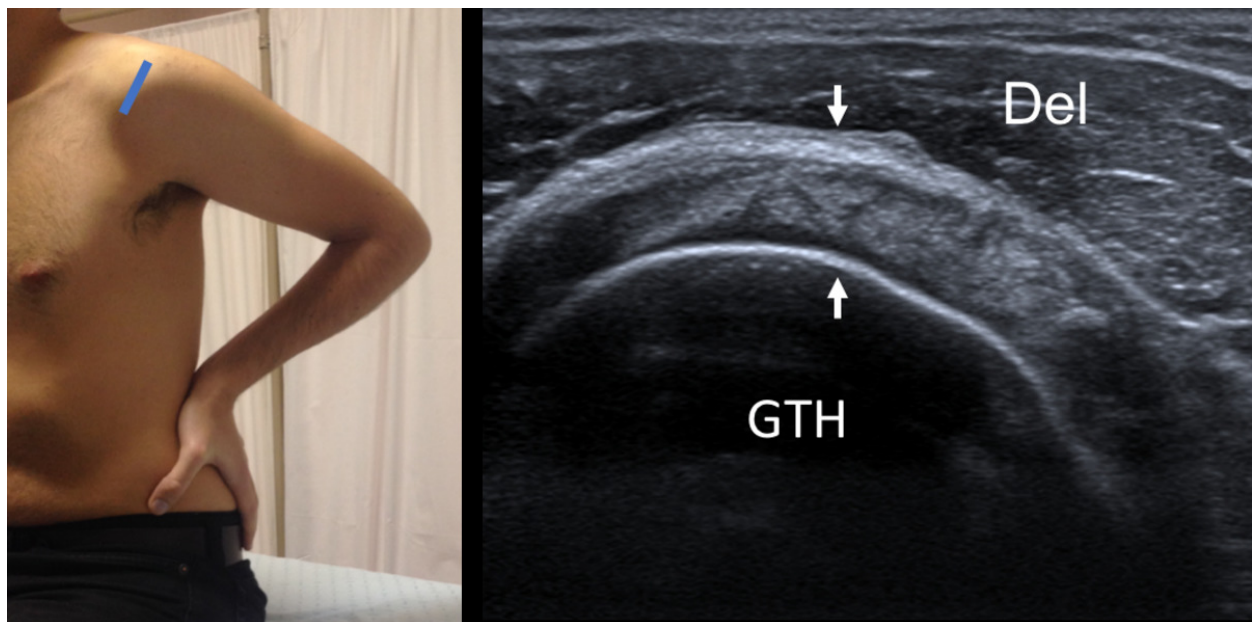


Fig. 5: Short axis of supraspinatus tendon - Probe placement and US normal imaging findings. Del, deltoid muscle; GTH, Greater tuberosity of the humerus; Arrows, supraspinatus tendon.

References: Radiology Department, Coimbra University Hospital - Coimbra/PT

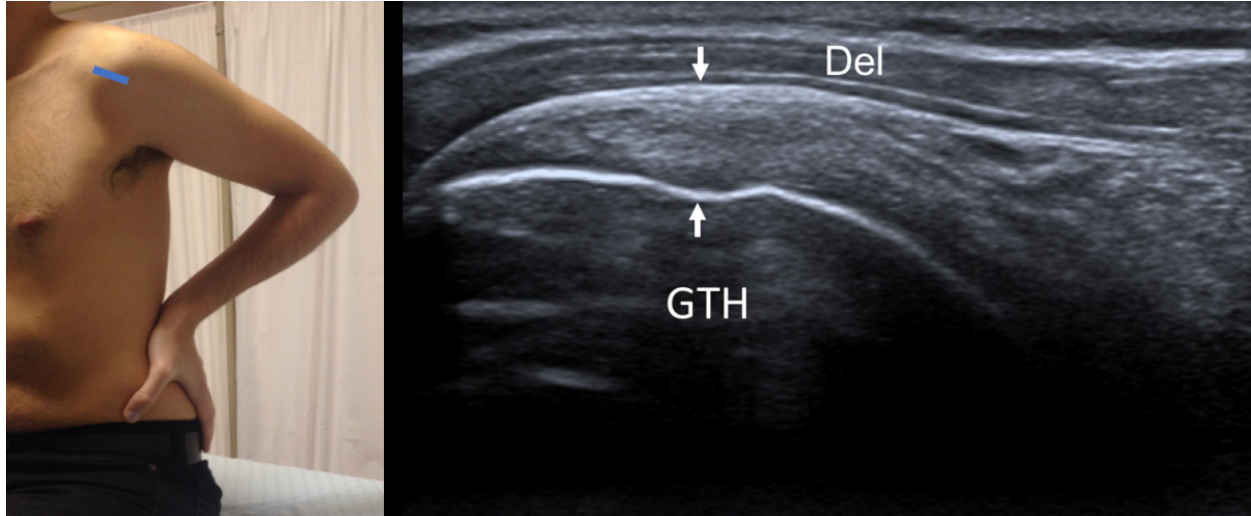


Fig. 6: Long axis of supraspinatus tendon - Probe placement and US normal imaging findings. Del, deltoid muscle; GTH, Greater tuberosity of the humerus; Arrows, supraspinatus tendon.

References: Radiology Department, Coimbra University Hospital - Coimbra/PT

4. ROTATOR INTERVAL

ANATOMY

The rotator interval is a triangular anatomic area in the anterosuperior aspect of the shoulder, which is defined by the coracoid process at its base, superiorly by the anterior margin of the supraspinatus tendon, and inferiorly by the superior margin of the subscapularis tendon. It is roofed by the rotator interval capsule, which is principally made up of the coracohumeral ligament. It contains the tendon of the long head of the biceps and the superior glenohumeral ligament.

TECHNIQUE AND EVALUATION

The rotator interval is best evaluated with the arm in external rotation, in the same position used in the evaluation of the supraspinatus.

The thin hyperechoic coracohumeral ligament can be identified superficial to the long head of the biceps tendon and the glenohumeral ligament is medial to the biceps tendon, with a thin and hyperechoic appearance. The combination of the coracohumeral ligament and superior glenohumeral ligament have a complex relationship which contributes to the biceps pulley, acting together to hold the long head of the biceps from subluxing or dislocating anteriorly.

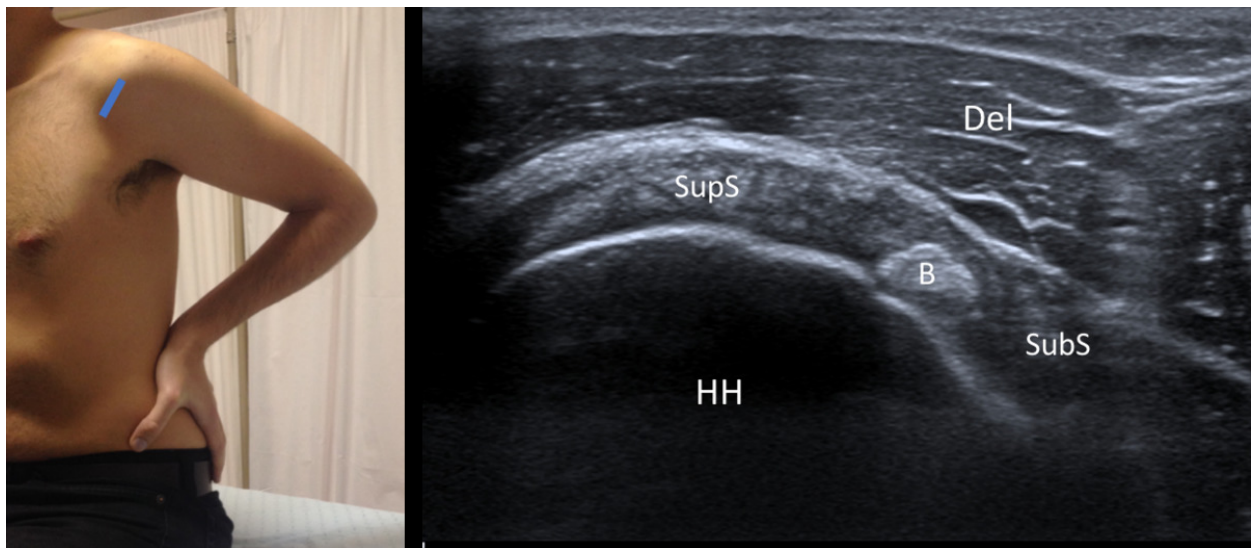


Fig. 7: Rotator Interval - Probe placement and US normal imaging findings. DM, deltoid muscle; B, Biceps tendon; HH, Humeral Head; Del, Deltoid muscle; SupS, Supraspinatus tendon; SubS, Subscapularis tendon.

References: Radiology Department, Coimbra University Hospital - Coimbra/PT

5. ACROMIO-CLAVICULAR JOINT

ANATOMY

The acromio-clavicular joint is located between the acromio and clavicle.

TECHNIQUE AND EVALUATION

The acromio-clavicular joint is best evaluated when the transducer is oriented along the long axis of the clavicle with the patient's arm in neutral position. This view optimizes the visualization of the joint space, synovium, capsule, and bony margins of the joint.

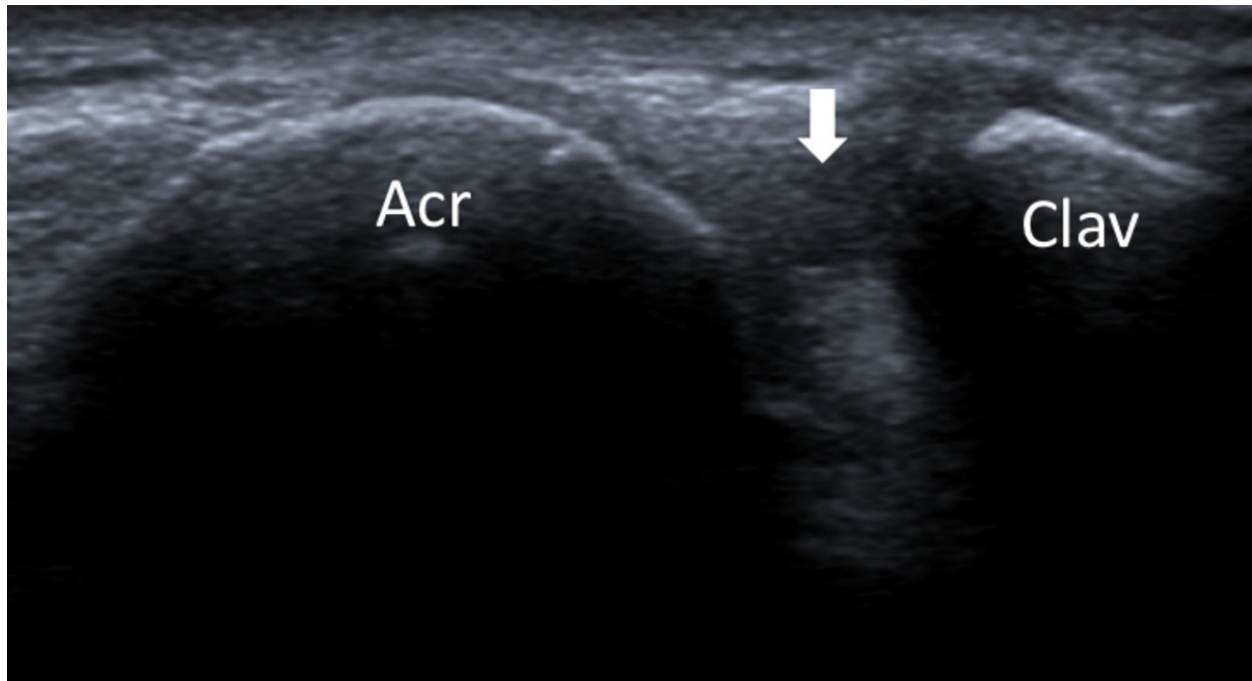


Fig. 8: Acromioclavicular joint - Probe placement and US normal imaging findings. Acr, acromion; Clav, clavicle; Arrow, acromio-clavicular joint space.

References: Radiology Department, Coimbra University Hospital - Coimbra/PT

6. SUBACROMIAL IMPINGEMENT

ANATOMY

Subacromial impingement is a clinical syndrome that occurs secondary to attrition between the coracoacromial arch and the supraspinatus tendon or subacromial bursa.

TECHNIQUE AND EVALUATION

A dynamic assessment is fundamental to evaluate the subacromial impingement. The probe is positioned with its medial margin at the lateral margin of the acromion, in

coronal oblique position, viewing the greater tuberosity. Then, the patient must abduct and elevate his arm internally rotated. During this maneuver, the supraspinatus and the subacromial-subdeltoid bursa should slide smoothly under the acromion.

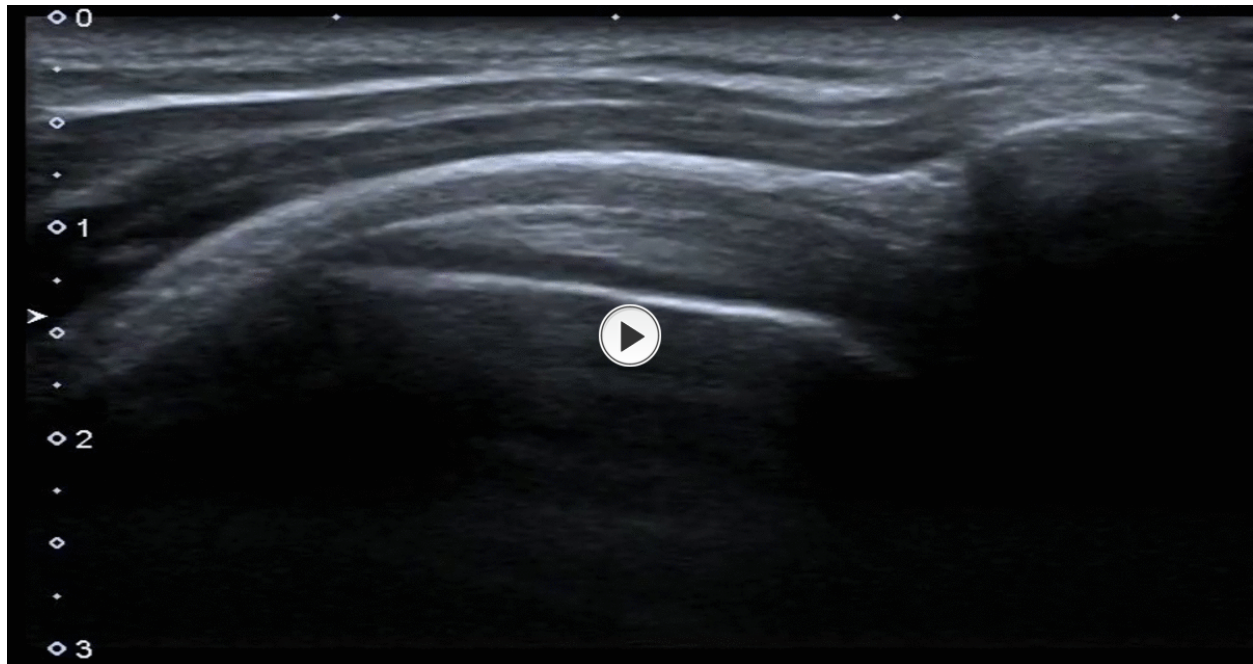


Fig. 9: Subacromial impingement - dynamic evaluation by ultrasonography.

References: Radiology Department, Coimbra University Hospital - Coimbra/PT

7. INFRASPINATUS AND TERES MINOR TENDONS

ANATOMY

The infraspinatus muscle is a thick triangular muscle, that arises from the medial part of the infraspinatous fossa (beneath the spine of the scapula) and runs laterally to insert on the middle facet of the greater tubercle of the humerus.

The teres minor arise just below the infraspinatus on the infraspinatous fossa and runs laterally to insert on the inferior facet of the greater tubercle of the humerus (and on the capsule of glenohumeral joint).

TECHNIQUE AND EVALUATION

The assessment must be realized by a posterior approach and the patient must have his elbow flexed and the palm place on the opposite shoulder (or his hand turned to the lap, with palm up).

The spine of the scapula is as optimal landmark, and the transducer must be placed just below the scapular spine in a slightly oblique axial plane, producing a long-axis view of the infraspinatus tendon, and following the tendon to it's insertion postero-laterally on the humeral head. In an inferior position, we can find the teres minor below the infraspinatus. The transducer is then rotated 90° to assess these tendons in short axis. The infraspinatus tendon is larger and longer than the teres minor tendon.

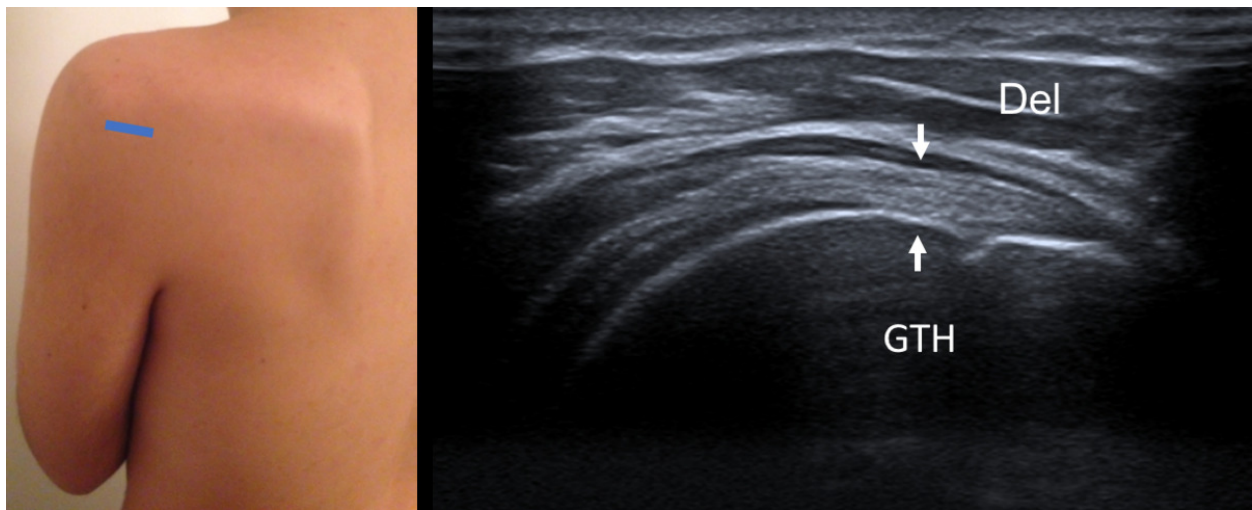


Fig. 10: Long axis of infraspinatus tendon - Probe placement and US normal imaging findings. Del, deltoid muscle; GTH, Greater tuberosity of the humerus; Arrows, infraspinatus tendon.

References: Radiology Department, Coimbra University Hospital - Coimbra/PT

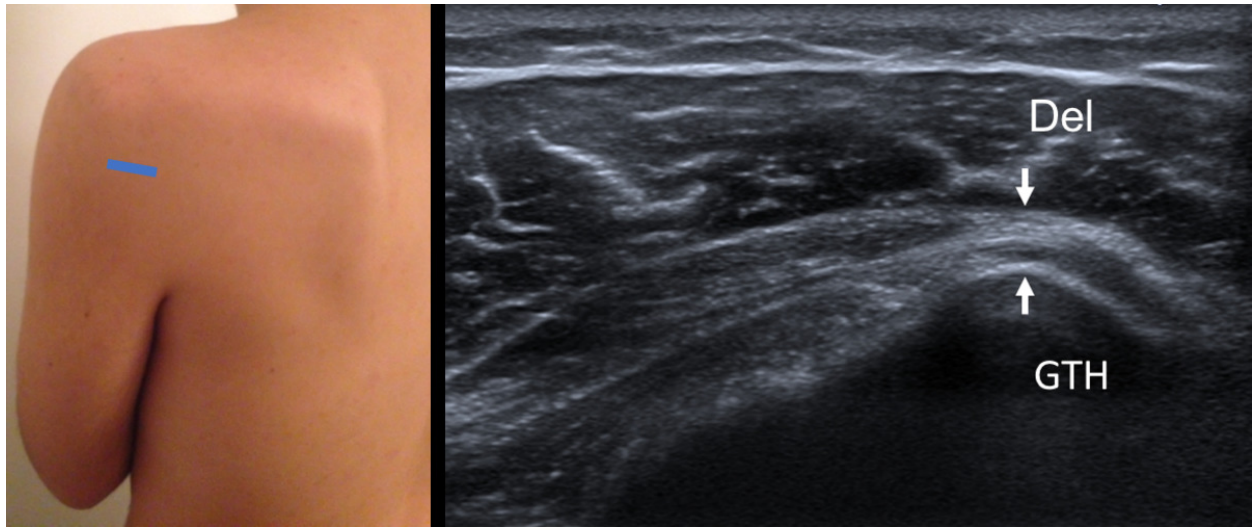


Fig. 11: Long axis of teres minor tendon - Probe placement and US normal imaging findings. Del, deltoid muscle; GTH, Greater tuberosity of the humerus; Arrows, teres minor tendon.

References: Radiology Department, Coimbra University Hospital - Coimbra/PT

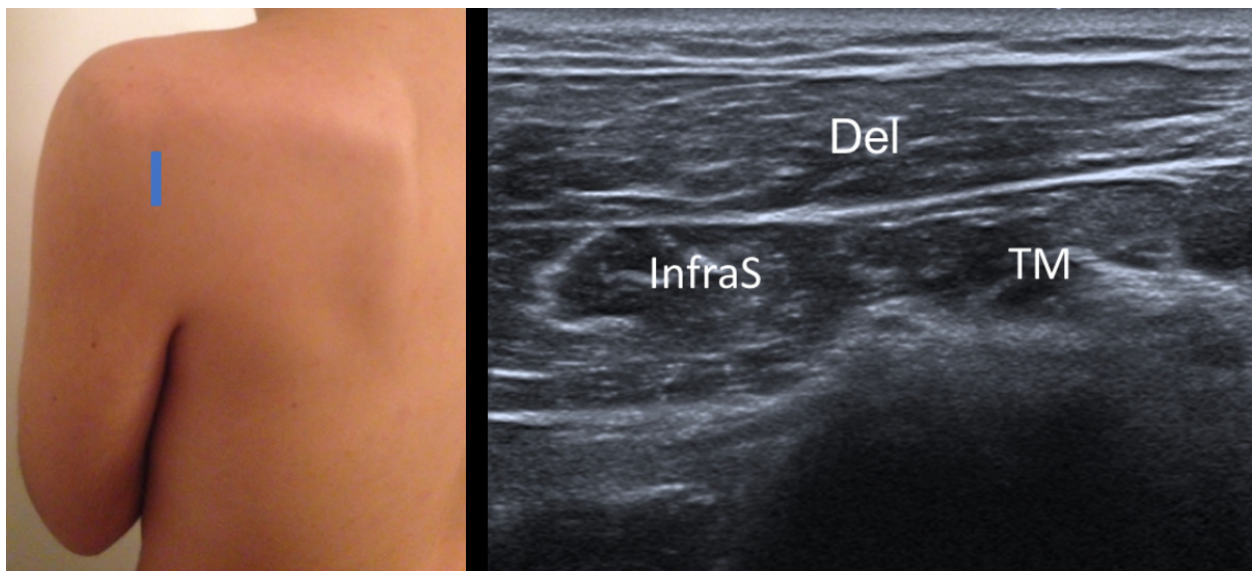


Fig. 12: Short axis of infraspinatus and teres minor muscles - Probe placement and US normal imaging findings. Del, deltoid muscle; InfraS, infraspinatus muscle; TM, teres minor muscle.

References: Radiology Department, Coimbra University Hospital - Coimbra/PT

8. POSTERIOR GLENOHUMERAL JOINT RECESS

ANATOMY

The glenohumeral joint includes the margins of the labrum and glenoid rim to the anatomic neck of the humerus.

TECHNIQUE AND EVALUATION

To evaluate the posterior recess, the transducer must slide medially on the posterior side of the joint while the patient's arm is positioned in the same position used to evaluate infraspinatus and teres minor tendons.

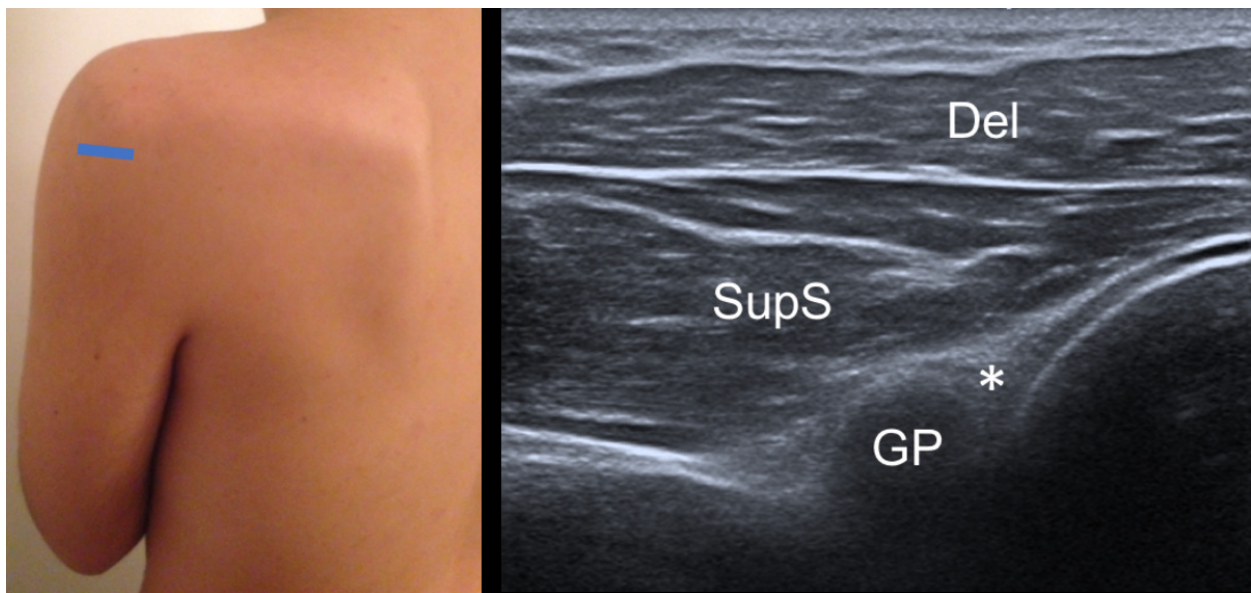


Fig. 13: Posterior glenohumeral joint recess - Probe placement and US normal imaging findings. Asterisk, posterior labrum; Del, deltoid muscle; SupS, Supraspinatus tendon; GP, glenoid process; HH, humeral head.

References: Radiology Department, Coimbra University Hospital - Coimbra/PT

Images for this section:

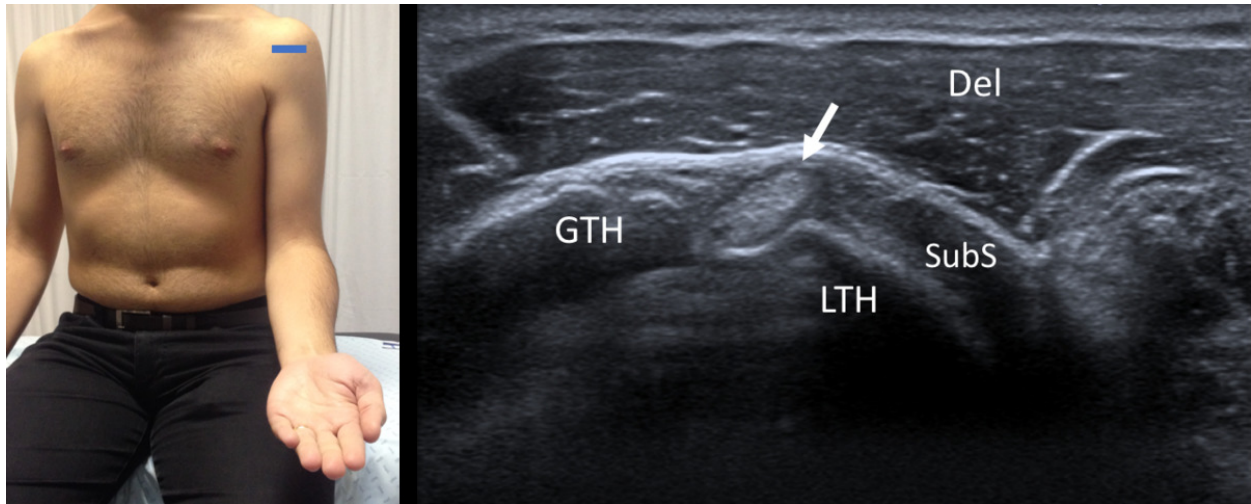


Fig. 1: Short axis of long head of the biceps tendon - Probe placement and US normal imaging findings. LTH, lesser tuberosity of the humerus; GTH, greater tuberosity of the humerus; Del, deltoid muscle; SubS, Subscapularis tendon; Arrow, long head of the biceps tendon

© Radiology Department, Coimbra University Hospital - Coimbra/PT

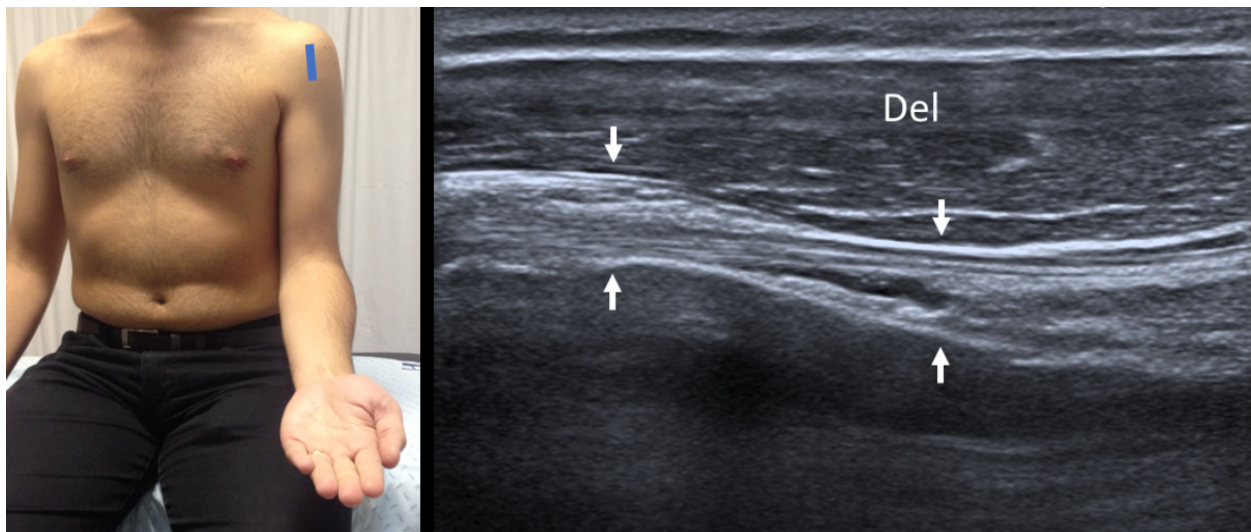


Fig. 2: Long axis of long head of the biceps tendon - Probe placement and US normal imaging findings. Del, deltoid muscle; Arrows, long head of the biceps tendon

© Radiology Department, Coimbra University Hospital - Coimbra/PT

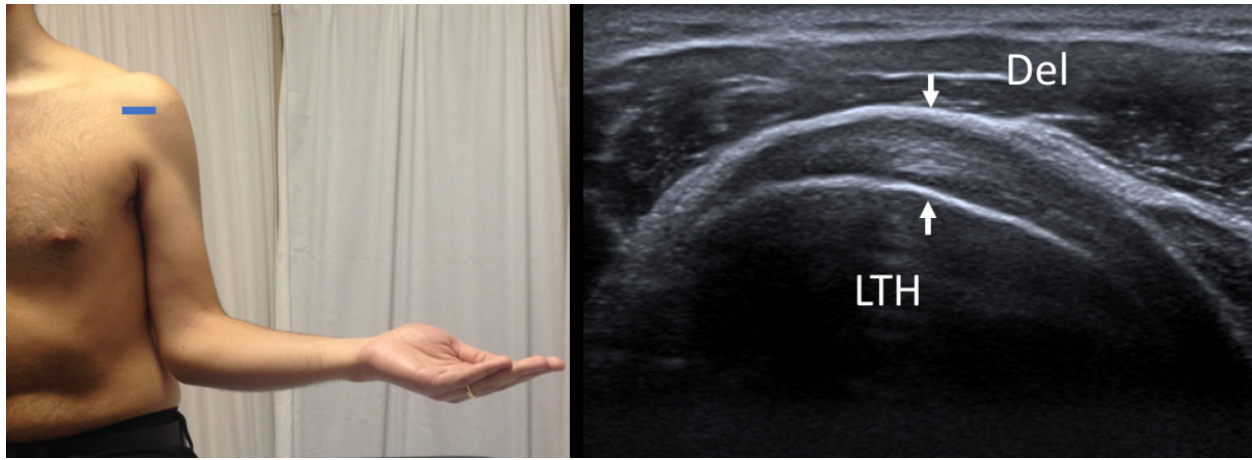


Fig. 3: Long axis of subscapularis tendon - Probe placement and US normal imaging findings. Del, deltoid muscle; LTH, Lesser tuberosity of the humerus; Arrows, subscapularis tendon.

© Radiology Department, Coimbra University Hospital - Coimbra/PT

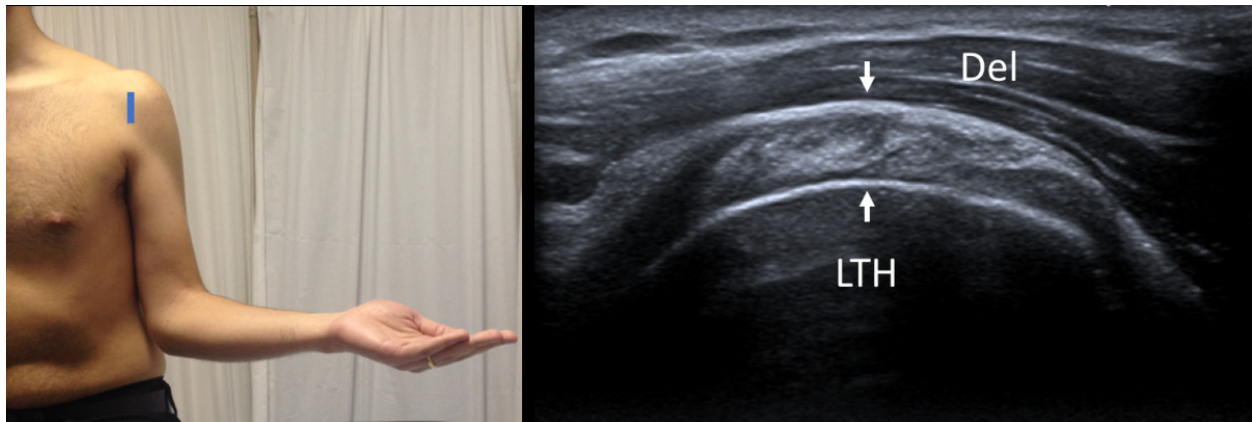


Fig. 4: Short axis of subscapularis tendon - Probe placement and US normal imaging findings. Del, deltoid muscle; LTH, Lesser tuberosity of the humerus; Arrows, subscapularis tendon.

© Radiology Department, Coimbra University Hospital - Coimbra/PT

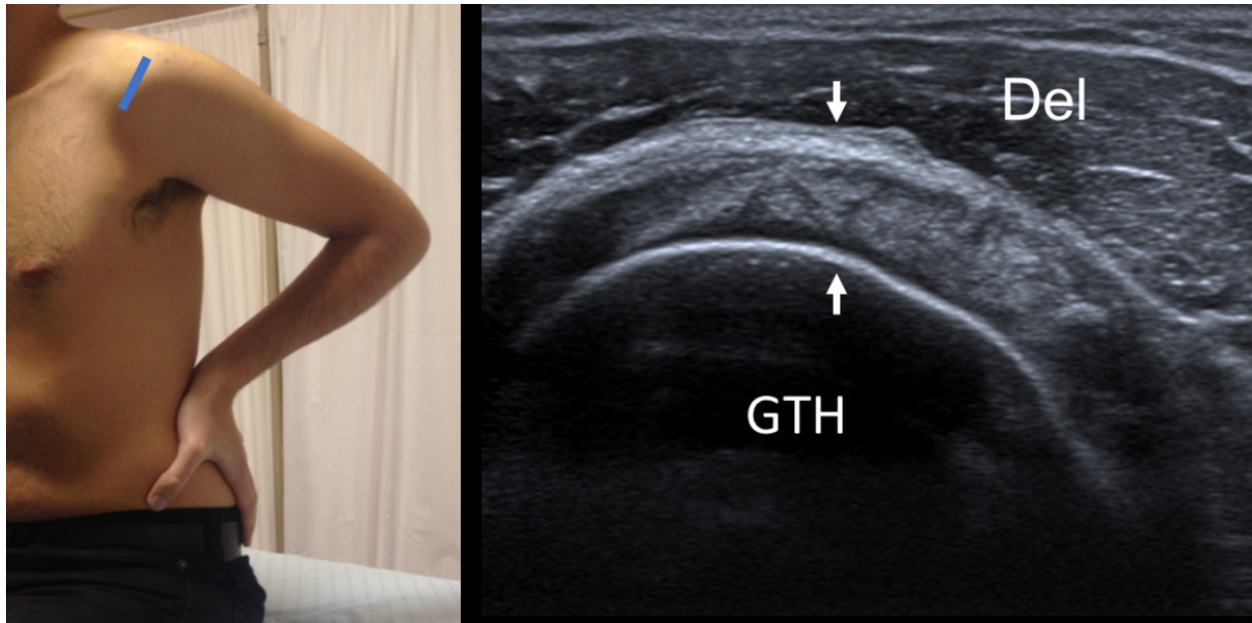


Fig. 5: Short axis of supraspinatus tendon - Probe placement and US normal imaging findings. Del, deltoid muscle; GTH, Greater tuberosity of the humerus; Arrows, supraspinatus tendon.

© Radiology Department, Coimbra University Hospital - Coimbra/PT

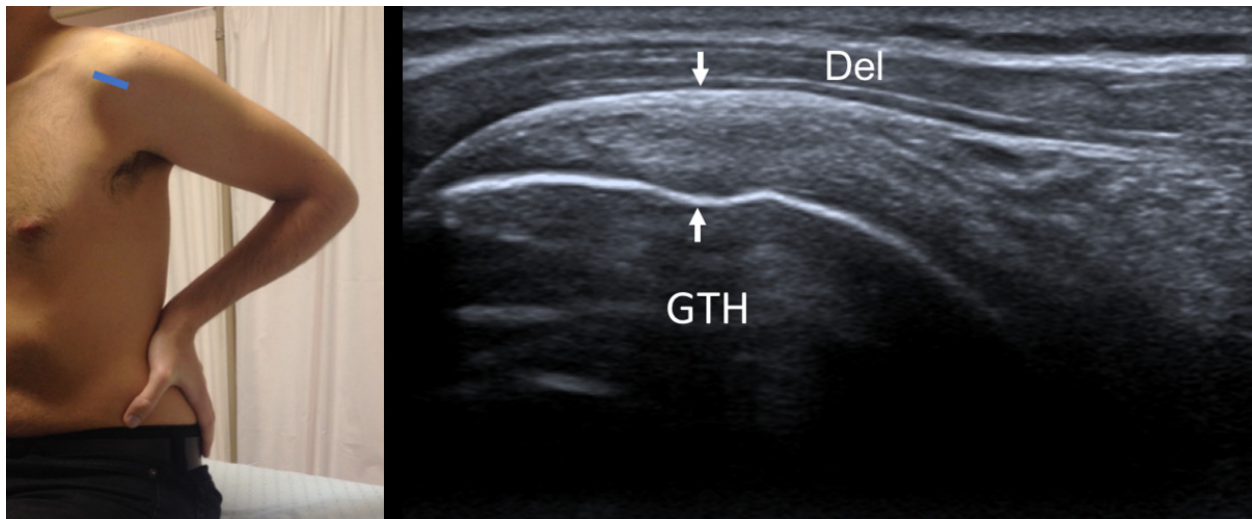


Fig. 6: Long axis of supraspinatus tendon - Probe placement and US normal imaging findings. Del, deltoid muscle; GTH, Greater tuberosity of the humerus; Arrows, supraspinatus tendon.

© Radiology Department, Coimbra University Hospital - Coimbra/PT

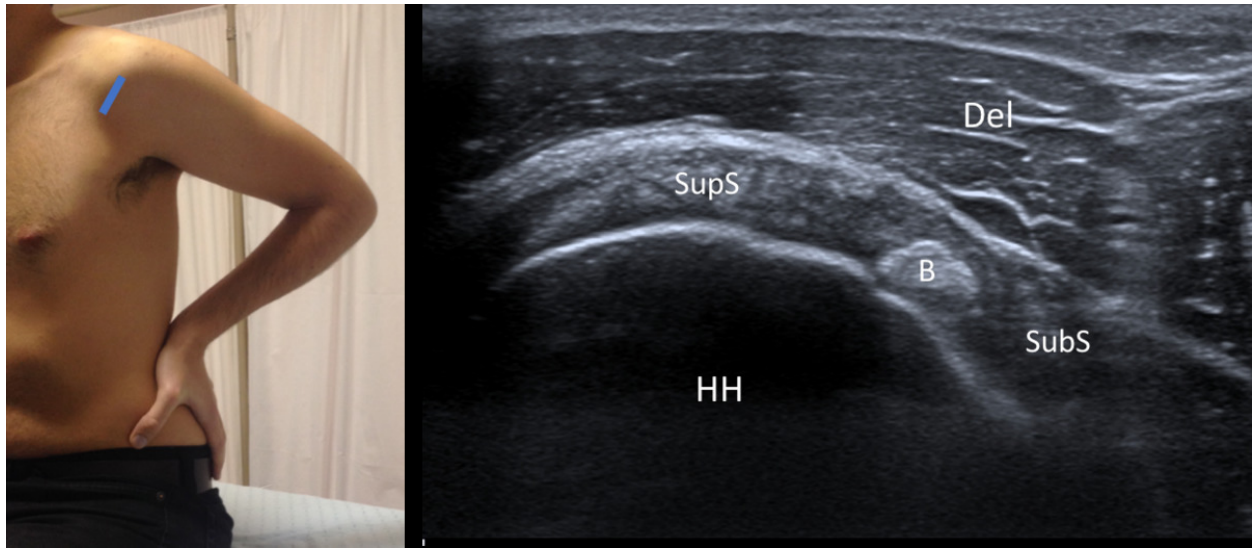


Fig. 7: Rotator Interval - Probe placement and US normal imaging findings. DM, deltoid muscle; B, Biceps tendon; HH, Humeral Head; Del, Deltoid muscle; SupS, Supraspinatus tendon; SubS, Subscapularis tendon.

© Radiology Department, Coimbra University Hospital - Coimbra/PT

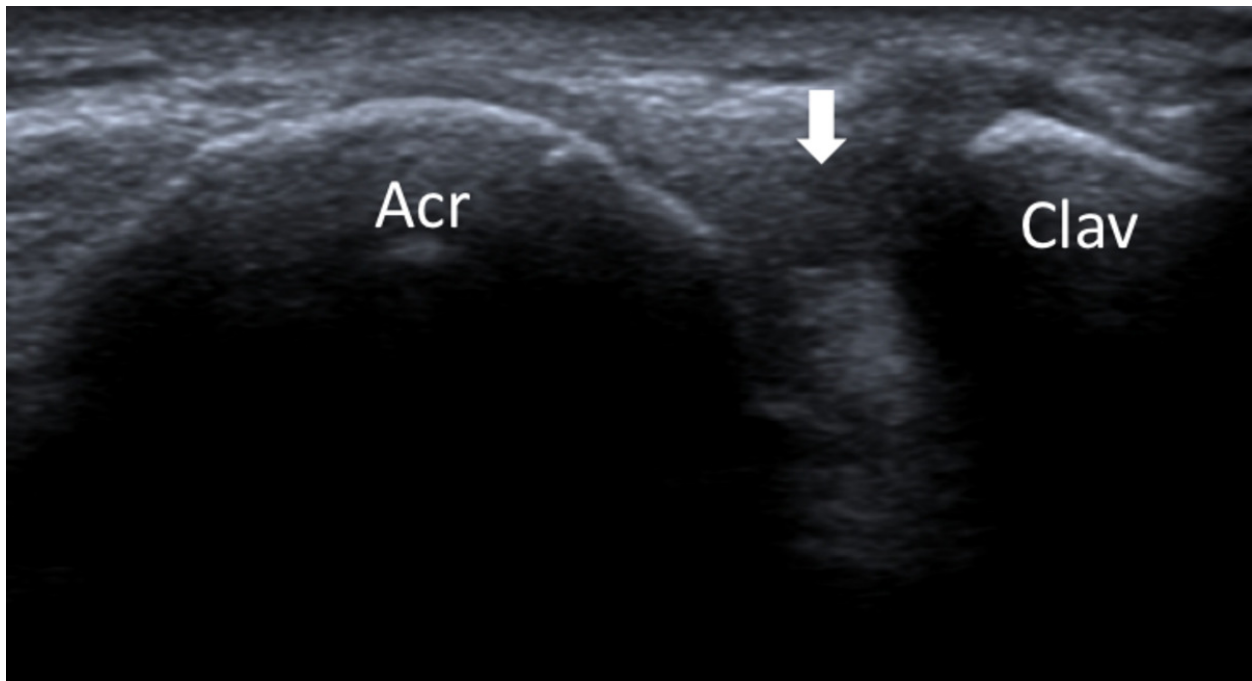


Fig. 8: Acromioclavicular joint - Probe placement and US normal imaging findings. Acr, acromion; Clav, clavicle; Arrow, acromio-clavicular joint space.

© Radiology Department, Coimbra University Hospital - Coimbra/PT

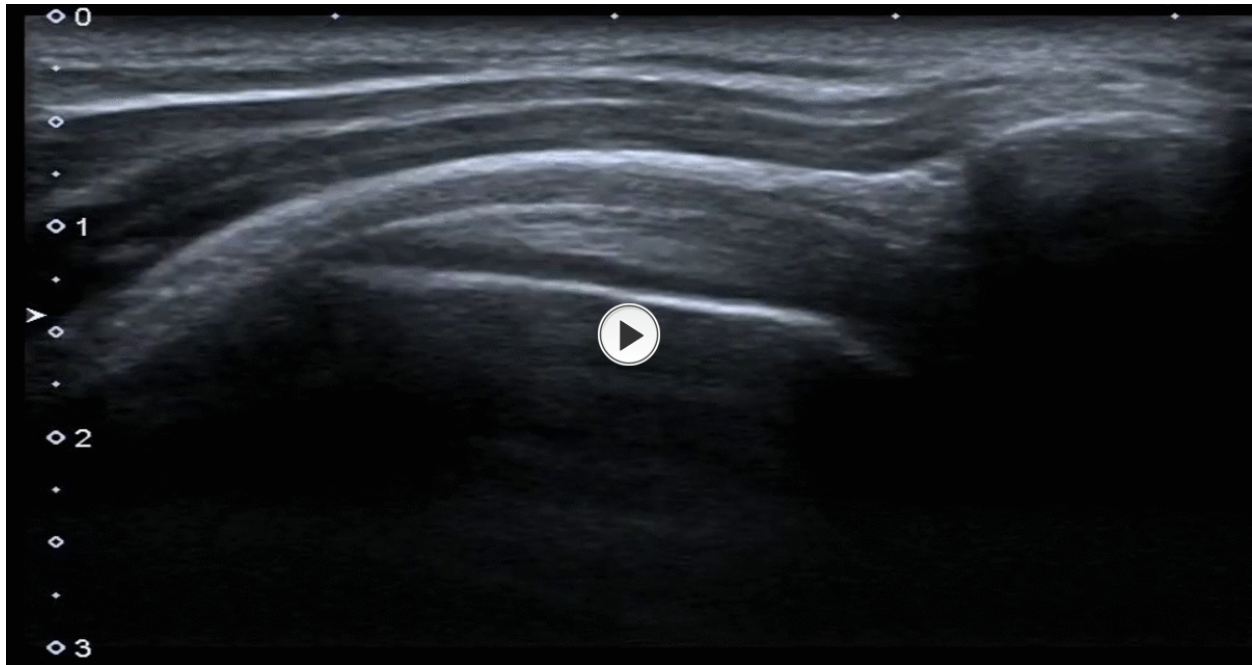


Fig. 9: Subacromial impingement - dynamic evaluation by ultrasonography.

© Radiology Department, Coimbra University Hospital - Coimbra/PT

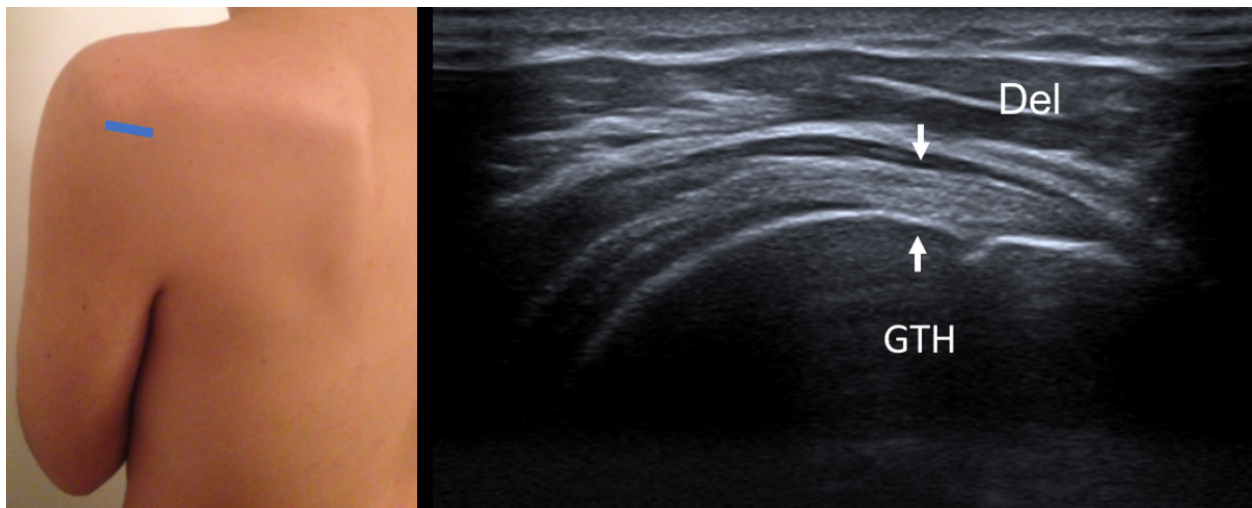


Fig. 10: Long axis of infraspinatus tendon - Probe placement and US normal imaging findings. Del, deltoid muscle; GTH, Greater tuberosity of the humerus; Arrows, infraspinatus tendon.

© Radiology Department, Coimbra University Hospital - Coimbra/PT

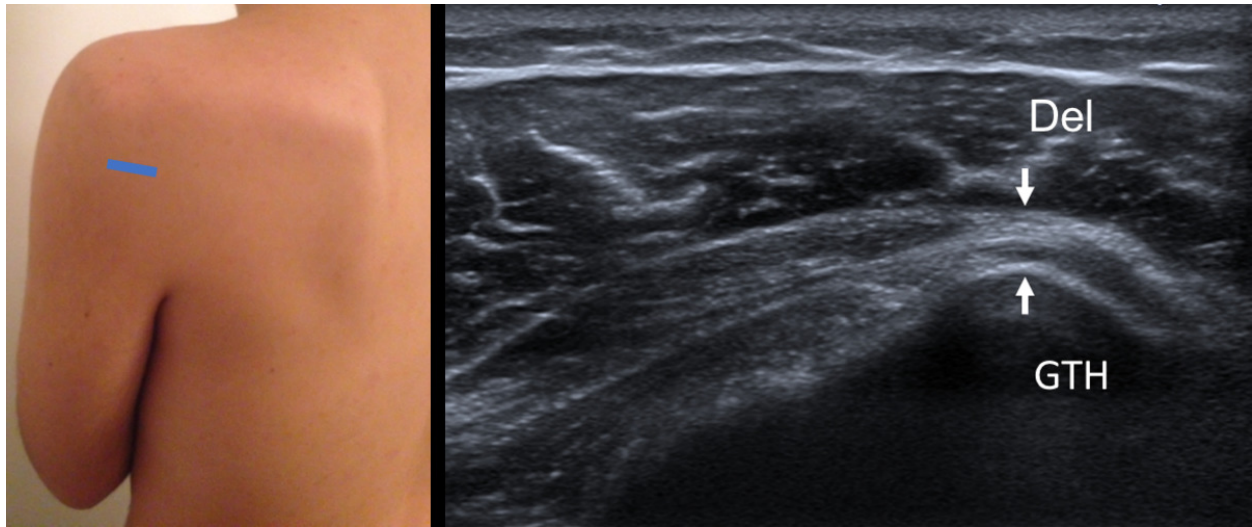


Fig. 11: Long axis of teres minor tendon - Probe placement and US normal imaging findings. Del, deltoid muscle; GTH, Greater tuberosity of the humerus; Arrows, teres minor tendon.

© Radiology Department, Coimbra University Hospital - Coimbra/PT

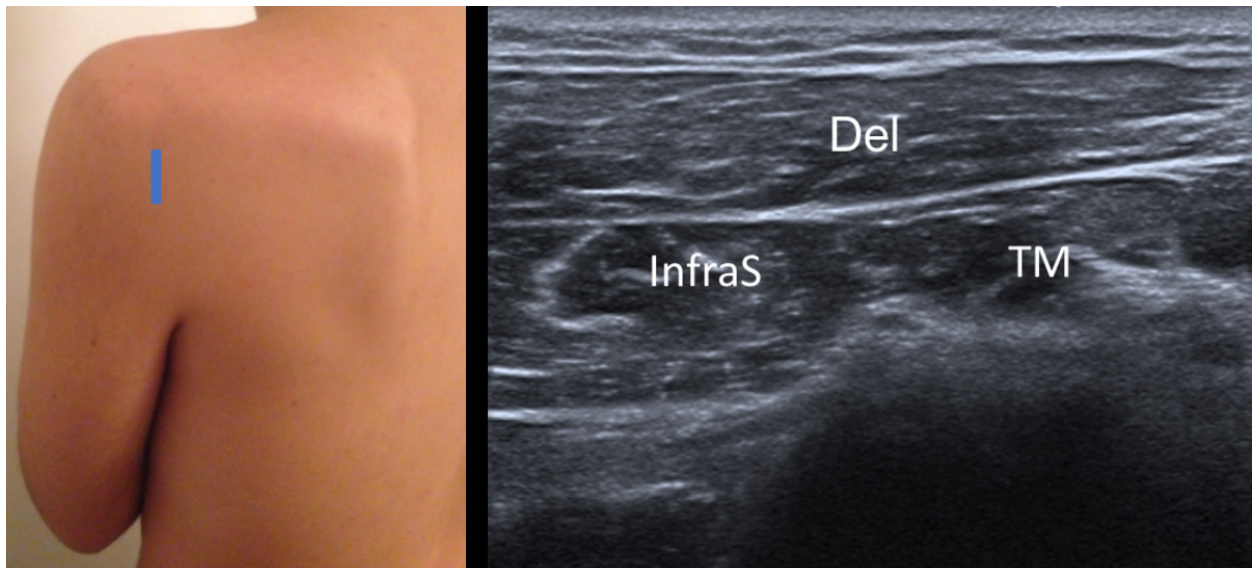


Fig. 12: Short axis of infraspinatus and teres minor muscles - Probe placement and US normal imaging findings. Del, deltoid muscle; InfraS, infraspinatus muscle; TM, teres minor muscle.

© Radiology Department, Coimbra University Hospital - Coimbra/PT

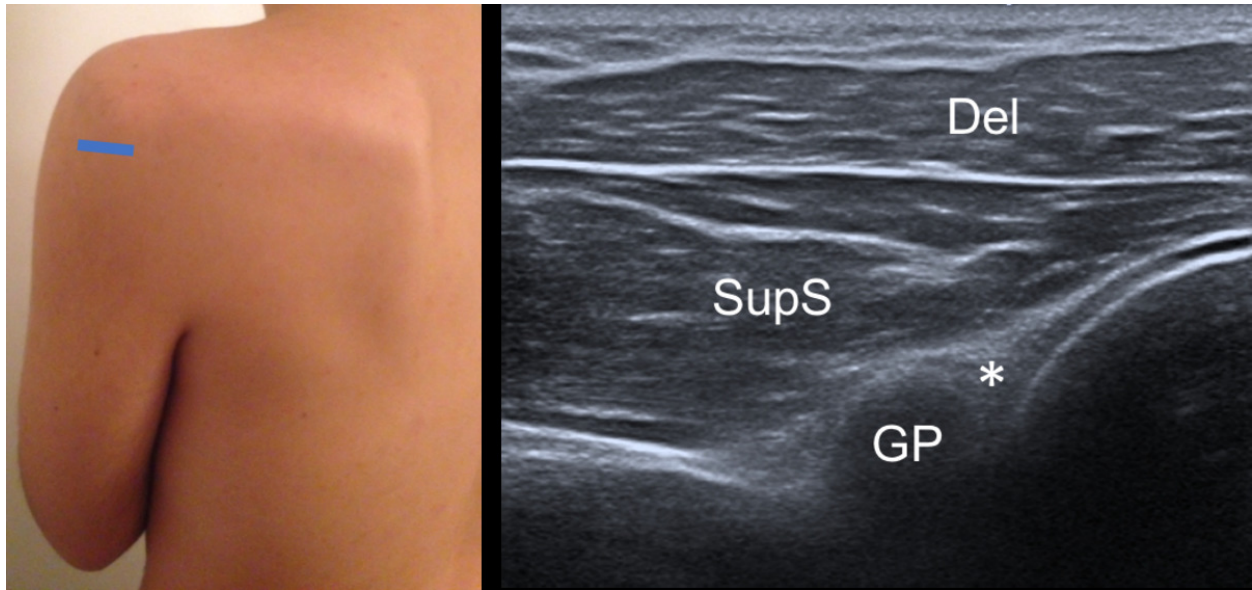


Fig. 13: Posterior glenohumeral joint recess - Probe placement and US normal imaging findings. Asterisk, posterior labrum; Del, deltoid muscle; SupS, Supraspinatus tendon; GP, glenoid process; HH, humeral head.

© Radiology Department, Coimbra University Hospital - Coimbra/PT

Conclusion

Ultrasonography represents a useful imaging modality for the assessment of a wide range of abnormalities involving the anatomic structures of the shoulder. It is, nevertheless, essential to have a thorough understanding of the anatomy and to perform ultrasonography of the shoulder on a regular basis and in a standardized way.

Personal information

References

1. Teefey SA. Shoulder sonography: why we do it. J Ultrasound Med. 2012 Sep; 31(9):1325-31
2. Jacobson JA. Shoulder US: anatomy, technique, and scanning pitfalls. Radiology. 2011 Jul; 260(1):6-16
3. Martinoli C. Musculoskeletal ultrasound: technical guidelines. Insights into Imaging. 2010 Jul; 1(3): 99-141
4. Petranova T, Vlad V, Porta F, Radunovic G, Micu MC, Nestorova R, Iagnocco A. Ultrasound of the shoulder. Med Ultrason. 2012 Jun; 14(2):133-40
5. Martinoli C, Bianchi S, Prato N, Pugliese F, Zamorani MP, Valle M, Derchi LE. US of the shoulder: non-rotator cuff disorders. Radiographics. 2003 Mar-Apr; 23(2):381-401
6. Singh JP. Shoulder ultrasound: What you need to know. The Indian Journal of Radiology & Imaging. 2012 Oct-Dec; 22(4): 284-292